

# Cystic Duct with Medial Spiral Insertion: A Case Report.

Ilija Golubović, Aleksandar Vukadinovic, Nebojša Ignjatović, Miroslav Stojanović

Clinic for Digestive Surgery, University Clinical Center Nis, 18000 Nis, Serbia.

**\*Corresponding Author:** Ilija Golubovic, Clinic for Digestive Surgery, University Clinical Center Nis, 18000 Nis, bul. dr Zorana Djindjica 48, 18000 Nis, Republic of Serbia.

**Received Date:** December 16, 2025 | **Accepted Date:** January 05, 2026 | **Published Date:** January 17, 2026

**Citation:** Ilija Golubović, Aleksandar Vukadinovic, Nebojša Ignjatović, Miroslav Stojanović, (2026), Cystic Duct with Medial Spiral Insertion: A Case Report, *International Journal of Clinical Case Reports and Reviews*, 33(3); DOI:10.31579/2690-4861/1019

**Copyright:** © 2026, Ilija Golubovic. This is an open-access article distributed under the terms of the Creative Commons Attribution License, which permits unrestricted use, distribution, and reproduction in any medium, provided the original author and source are credited.

## Abstract:

**Introduction:** The biliary system is well known for its anatomical variability. Precise imaging and evaluation of the cystic duct are essential for surgeons and interventional radiologists.

**Case report:** We reported a rare case of cystic duct variation. Coronal oblique 3D magnetic resonance cholangiopancreatography (MRCP) showed posterior spiral course of cystic duct with medial spiral insertion to the mid part of the extrahepatic bile duct. Intraoperative cholangiogram also confirms the finding.

**Conclusions:** Specific anatomical variations might require modifications to the surgical approach. Understanding cystic duct anatomy, variants, and disease processes aids in better diagnosis and interpretation of imaging results. MRCP is essential in giving important information on cystic duct anatomy and helps in preparing for and reducing the risk of complications during percutaneous, endoscopic, and surgical procedures.

**Key words:** cystic duct; anatomical variations; magnetic resonance cholangiopancreatography

## Introduction

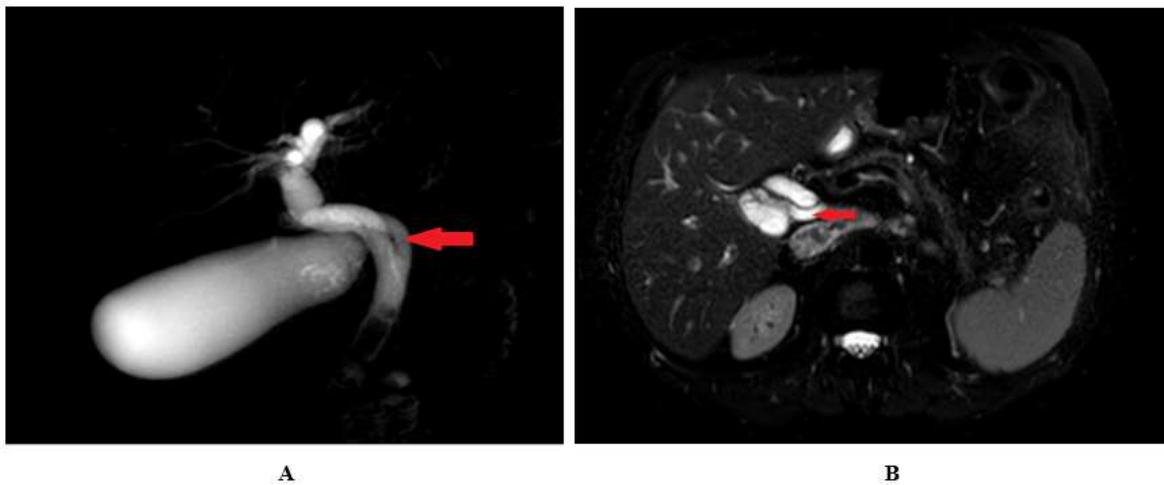
The biliary system is well known for its anatomical variability which are usually unrecognized [1]. With the growing frequency of laparoscopic cholecystectomy, hepatobiliary surgery, and transcholecystic biliary treatments, precise imaging and evaluation of the cystic duct are essential for surgeons and interventional radiologists [2]. The biliary tract consists of intrahepatic and extrahepatic components. The cystic duct is roughly 2-4 cm long and 1-5 mm in diameter, connecting the neck of the gallbladder to the common hepatic duct (CHD) and forming the common bile duct (CBD). The cystic duct's point of insertion into the CHD varies. It typically enters the CHD from the right lateral aspect. It joins the CHD approximately halfway between the hepatic confluence and the ampulla of Vater [3].

## Case Report:

Herein, we reported a rare case of cystic duct with medial spiral insertion to the mid part of the extrahepatic bile duct. A 60-year-old male was admitted to our department due to abdominal pain for 7 days. The patient had a five-year history of recurrent visits to the hospital for right upper quadrant pain, nausea, and vomiting. Alcohol abuse was denied. On

admission he had normal vital signs. Physical examination demonstrated right upper quadrant tenderness without peritoneal signs with negative clinical Murphy's sign. His blood work showed a white blood cell count of 12,500 /microliter, alanine aminotransferase of 218 U/L, aspartate aminotransferase of 159 U/L, alkaline phosphatase of 100 U/L, and total bilirubin of 1.4 mg/dL.

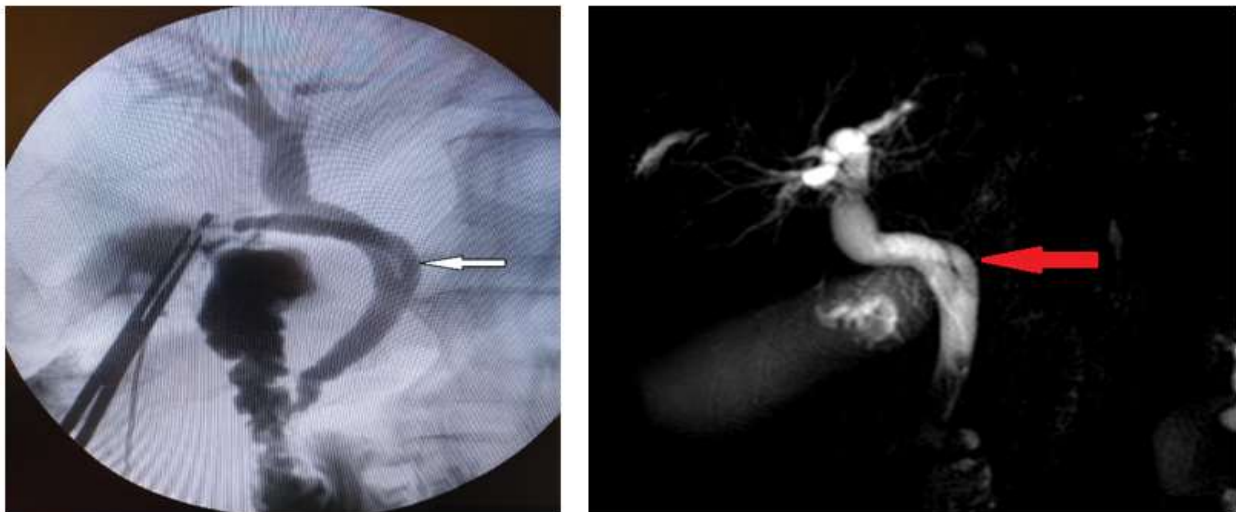
Ultrasound of the abdomen and pelvis revealed a dilated gallbladder with a thicker wall and with stones. The common bile duct (CBD) measured 15 mm in diameter, and stones were visible within it. Furthermore, the ultrasonography revealed the dilatation of the intrahepatic bile ducts. MRCP was conducted using 1.5 T MRI (Ingenia; Philips Healthcare, Best, the Netherlands) in the coronal, axial, and sagittal planes in accordance with standard protocol. T2-weighted sequences in multi planar reconstruction were used for the evaluation. Respiratory-triggered T2 SPAIR axial and T2 coronal sequences with slice thickness of 5 mm, comprising the liver and region, were acquired. The MRCP revealed a gallbladder with 3 small stones and a 16 mm-diameter common bile duct (CBD) with four stones visible inside. Furthermore, coronal oblique 3D MRCP showed posterior spiral course of cystic duct with medial insertion with CHD (**Figure 1**)



**Figure 1:** Coronal oblique 3D MR cholangiopancreatography (A and B) and T2w-SPAIR sequence in axial plane (C) show posterior spiral course of cystic duct (red arrow) with medial insertion with CHD.

Due to the large number of adhesions from previous operations, the laparoscopic approach was abandoned, and open cholecystectomy with bile duct exploration was indicated for symptomatic choledocholithiasis and acute on chronic cholecystitis.

Before the end of the operation, intraoperative cholangiogram was performed through the cystic duct, which showed in the affirmative spiral course of cystic duct with medial insertion with CHD, intact CBD, CHD, as well as right and left hepatic ducts without stones (**Figure 2**).



**Figure 2:** Intraoperative cholangiogram shows spiral course of cystic duct (white arrow) with medial insertion with CHD.

The patient's liver function tests returned to normal after surgery. On the third postoperative day after surgery, the drain was removed, and the patient was tolerating diet. At his 2- and 4-week post-operative assessments in the outpatient clinic, there were no concerns regarding a bile leak or any problems. The pathology report showed acute on chronic cholecystitis.

### Discussion:

Ultrasonography (US), computed tomography (CT), endoscopic retrograde cholangiopancreatography (ERCP), percutaneous transhepatic cholangiography (PTC), T-tube cholangiography, intraoperative cholangiography (IOC), magnetic resonance cholangiopancreatography (MRCP), and cholescintigraphy can all be used to evaluate the biliary system [4].

In one set of studies incorporating IOC, only 57% of cases yielded conclusive results, hence it is not frequently conducted [5]. To address these limitations, MRCP is considered as the primary imaging modality. MRCP has a reported accuracy of 94.8% when compared to CT and US for detecting the anatomical variants. MRCP is crucial for providing essential data regarding cystic duct anatomy in cross-section and three-dimensional reconstruction images of the biliary tree, and it considerably improves the safety of laparoscopic cholecystectomy [6]. Different cystic duct variations are described in the literature depending on their length, course, and site of insertion with CHD. Sarawagi et al. (2016) presented some variations which are clinically more important (Table 1). In their study medial insertion was seen in 16% of cases, of which 4% were low medial insertions [7].

I	low insertion of cystic duct
II	parallel course of cystic duct with CHD
III	anterior or posterior spiral course with medial insertion
IV	absent or short cystic duct (length < 5 mm)
V	aberrant drainage of cystic duct to right hepatic or left hepatic duct
VI	aberrant or accessory intrahepatic ducts draining into cystic duct
VII	double cystic duct

Abbreviation: CHD: the common hepatic duct

**Table 1:** Different cystic duct variations which are clinically more important.

## Conclusions:

In conclusion, we reported a rare case of cystic duct with medial spiral insertion to the mid part of the extrahepatic bile duct. Specific anatomical variations might require modifications to the surgical approach. Understanding cystic duct anatomy, variants, and disease processes aids in better diagnosis and interpretation of imaging results. In addition to greatly improving the safety of laparoscopic cholecystectomy, MRCP is essential in giving important information on cystic duct anatomy in cross-section and three-dimensional reconstruction images of the biliary tree. Prior understanding of the cystic duct's morphology and variations would be extremely helpful in preparing for and reducing the risk of problems during percutaneous, endoscopic, and surgical procedures.

## Acknowledgements

**Funding:** None.

**Conflicts of Interest:** The authors have no conflicts of interest to declare.

**Ethical Statement:** The authors are accountable for all aspects of the work in ensuring that questions related to the accuracy or integrity of any part of the work are appropriately investigated and resolved.

## References

1. K Kashyap R, Bozorgzadeh A, Abt P, et al. (2008). Stratifying risk of biliary complications in adult living donor liver

transplantation by magnetic resonance cholangiography. *Transplantation*; 85:1569-1572.

2. Fujimoto N, Tomimaru Y, Yamamoto T, et al. (2020). Clinical investigation of the cystic duct variation based on the anatomy of the hepatic vasculature. *Surg Today*; 50:396-401.
3. Netter FH. The Ciba collection of medical illustrations. Digestive system. Part III. Liver, biliary tract and pancreas. Summit: Ciba Pharmaceutical 1957;22-24.
4. KC S, Banjade UR, Ghimire P. (2024). Anatomical variations of the cystic duct assessed by magnetic resonance cholangiopancreatography (MRCP): a cross-sectional study at tertiary center of Nepal. *J Patan Acad Health Sci*; 11:15-20.
5. Miron A, Popa LG, Toma EA, et al. (2023). The Curious Case of the Choledochal Cyst-Revisiting the Todani Classification: Case Report and Review of the Literature. *Diagnostics (Basel)*; 13:1059.
6. Jan RU, Shah SG, Shah AA, et al. (2023). Frequency of various anatomical variation of the cystic duct in patients with Cholelithiasis: A Descriptive Study. *JPTCP*; 30:1008-1003.
7. Sarawagi R, Sundar S, Gupta SK, et al. (2016). Anatomical Variations of Cystic Ducts in Magnetic Resonance Cholangiopancreatography and Clinical Implications. *Radiol Res Pract*;



This work is licensed under Creative Commons Attribution 4.0 License

To Submit Your Article Click Here:

[Submit Manuscript](#)

DOI:10.31579/2690-4861/1019

### Ready to submit your research? Choose Auctores and benefit from:

- fast, convenient online submission
- rigorous peer review by experienced research in your field
- rapid publication on acceptance
- authors retain copyrights
- unique DOI for all articles
- immediate, unrestricted online access

At Auctores, research is always in progress.

Learn more <https://auctoresonline.com/journals/international-journal-of-clinical-case-reports-and-reviews>