

MRI finding of Rathke Cleft Cyst in a 35-Year Old African Woman: A Case Report

Usman Aminu Umar ^{1*}, Dahiru Mohammed Yunusa ², Sule Muhammad Baba ³

¹Department of Radiology, Gombe State University, Gombe State, Nigeria.

²Department of Radiology, Modibbo Adama University, Adamawa State, Nigeria.

³Department of Radiology, Usman Danfodiyo University, Sokoto State, Nigeria.

***Corresponding Author:** Aminu Umar Usman, Department of Radiology, Gombe State, University, Gombe State, Nigeria.

Received Date: February 13, 2025; **Accepted Date:** February 20, 2025; **Published Date:** February 27, 2025

Citation: Usman A. Umar, Dahiru M. Yunusa, Sule M. Baba, (2025), MRI finding of Rathke Cleft Cyst in a 35-Year Old African Woman: A Case Report, *Clinical Medical Reviews and Reports*, 7(1); DOI:10.31579/2690-8794/252

Copyright: © 2025, Aminu Umar Usman. This is an open access article distributed under the Creative Commons Attribution License, which permits unrestricted use, distribution, and reproduction in any medium, provided the original work is properly cited.

Abstract

Rathke cleft cysts (RCC) are non-neoplastic cysts arising from the embryonic remnants of Rathke pouch of the pituitary gland primarily occupying the sellar space but can have suprasellar extension. Clinically it poses a diagnostic challenge as the symptoms may mimic other sellar and juxtasellar lesions. Magnetic Resonance Imaging (MRI) is the mainstay imaging modality for its diagnosis.

The case presented is RA, a 35-year old woman with recurrent headache, poor vision, amenorrhoea, loss of libido and occasional galactorrhea. MRI revealed expansion of the sella with a well-defined fairly rounded rim enhancing lesion measuring 15 X 14 X 15mm (width X AP X H) with compression of the optic chiasma. She was placed on hormonal therapy with remarkable improvement of symptoms and referred to Neurosurgeons for definitive treatment.

Keywords: Rathke Cleft cyst; Pituitary gland; Magnetic Resonance Imaging

Introduction

Rathke cleft cysts (RCC) also known as pars intermedia cysts are non-neoplastic cysts arising from the embryonic remnants of Rathke pouch of the pituitary gland[1]. Thus they develop as cystic lesions located between the anterior and posterior lobes of the pituitary gland[1]. They occupy the sellar space, but can have suprasellar extension.

They are common incidental findings in 11–22 % of autopsies [2-4]. Their peak incidence falls between the fourth and the sixth decade of life. They are three times more frequent among women [5]. It is rarely seen in childhood[3].

Usually, vast majority of Rathke cleft cysts are asymptomatic when less than 3mm in size [6]. When large, the typical symptoms include headache, visual loss and endocrinologic dysfunction [7-8].

Magnetic Resonance Imaging (MRI) is the primary diagnostic technique for RCC due to its high soft tissue resolution [9]. It also determines the cystic content and fluidity of the cyst which is useful in for subsequent patient's management [10].

Symptomatic RCC require surgical excision. Patients should be monitored for at least five years following surgery as the risk of recurrence may even reach 50%[1]. Radiotherapy may prove effective in the treatment of recurrent RCC [11]. Asymptomatic cases however require observation and serial monitoring [12-13].

Case Report

Mrs RA, a 35-year woman who was referred from a private hospital facility in Yola for a brain MRI with One-year history of recurrent headache which was dull aching in nature initially frontal and later became generalised with associated poor vision. She also has amenorrhoea for three months with marked reduction in libido. There is occasional galactorrhea. No heat or cold intolerance. No convulsion or loss of consciousness.

Physical examination was within normal limit. Visual examination revealed loss of vision in the outer (temporal) halves of the visual fields. Visual acuity and Fundoscopic examinations done were normal in both eyes.

Other cranial nerves assessment was normal. No lateralising sign or loss of muscle power.

Breast examinations revealed bilateral well developed breasts. No area of tenderness or palpable mass. However, breast milk was expressed on gentle pressure more on the right.

Hormonal assessment revealed hyperprolactinaemia with serum prolactin of 380ng/dl (normal value is 5 – 40ng/dl). Other systemic examinations were also normal.

Complimentary skull x-ray (Occipitofrontal and lateral views) show normal cranial vault, sutures and sella tursica. No craniofacial disproportion is noted.

Magnetic Resonance Imaging (MRI) revealed expansion of the sella with a well-defined fairly rounded lesion measuring 15 X 14 X 15mm (width X AP X H). It is hypointense on T1W, hyperintense on T2W and suppressed on FLAIR sequence. Rim enhancement is seen post contrast. The mass is inseparable from the optic chiasma suggestive of compression.

Radiological diagnosis of Rathke cleft cyst was made with a differential of Cystic pituitary macroadenoma.

Patient was placed on Bromocriptin tablets with remarkable improvement of the galactorrhea and normalisation of the prolactin level. She was also referred to the gynaecologist for the menstrual irregularity and a private Neurology centre in Lagos for definitive treatment of the primary Rathke's cleft cyst.

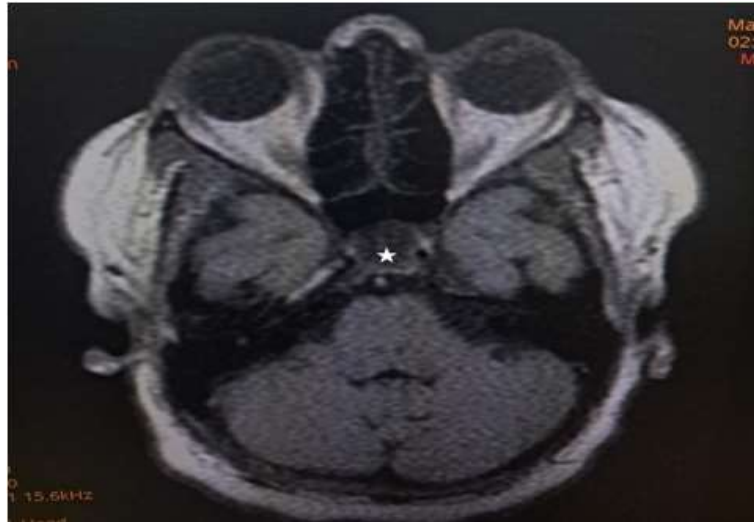

Figure 1: Axial T1W image of the brain showing a hypointense rounded intrasellar mass lesion (white asterisk)

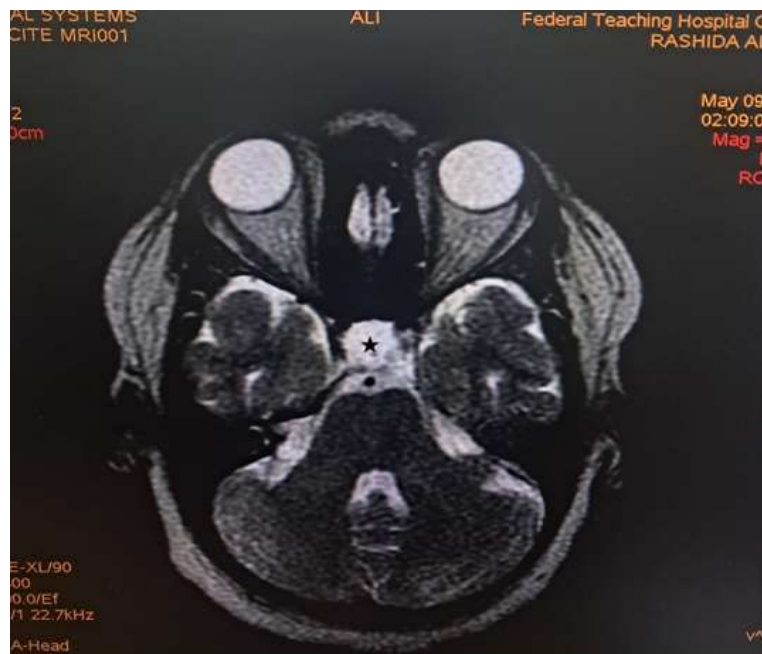


Figure 2: Axial T2W image of the brain showing a hyperintense rounded intrasellar mass lesion (black asterisk)

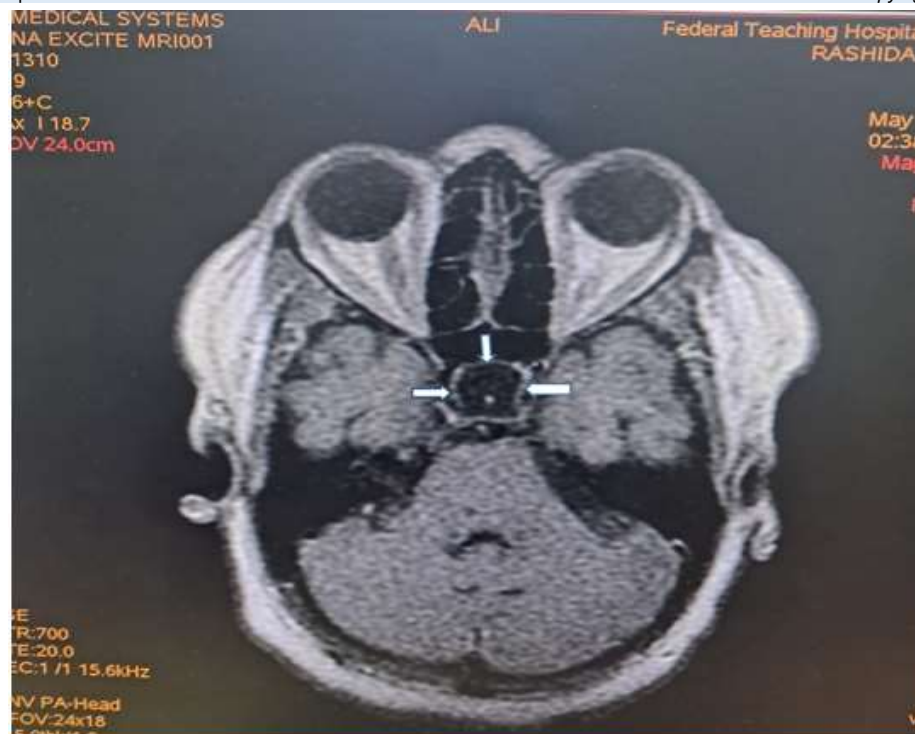

Figure 3: Axial T1W post contrast image of the brain showing a marginal (rim) enhancement of the hypointense rounded intrasellar mass lesion (white arrows)

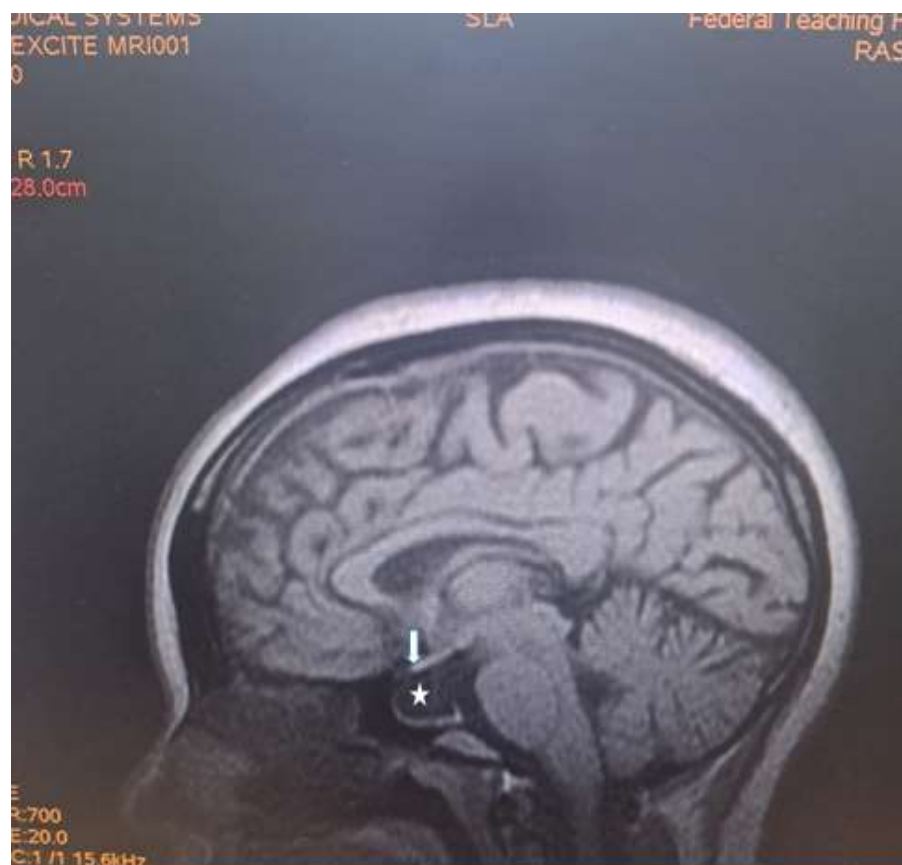

Figure 4: Sagittal T1W image of the brain showing a hypointense rounded intrasellar mass lesion (white asterisk) with obliteration of the optic chiasma (white arrow)

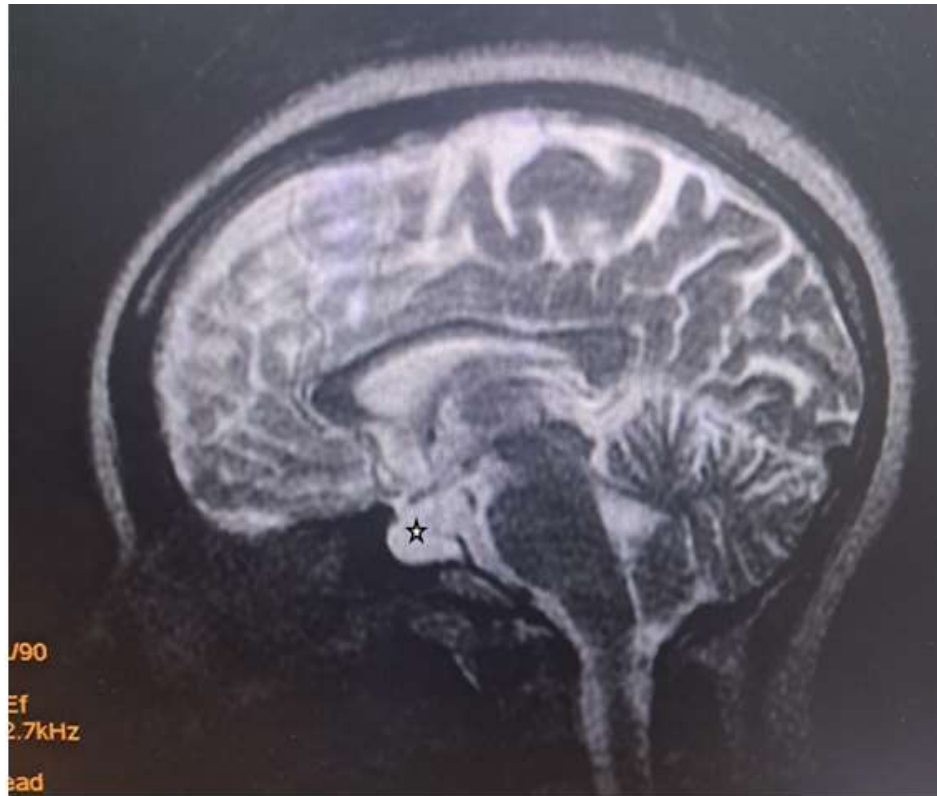


Figure 5: Sagittal T2W image of the brain showing a hyperintense rounded intrasellar mass lesion (black asterisk)

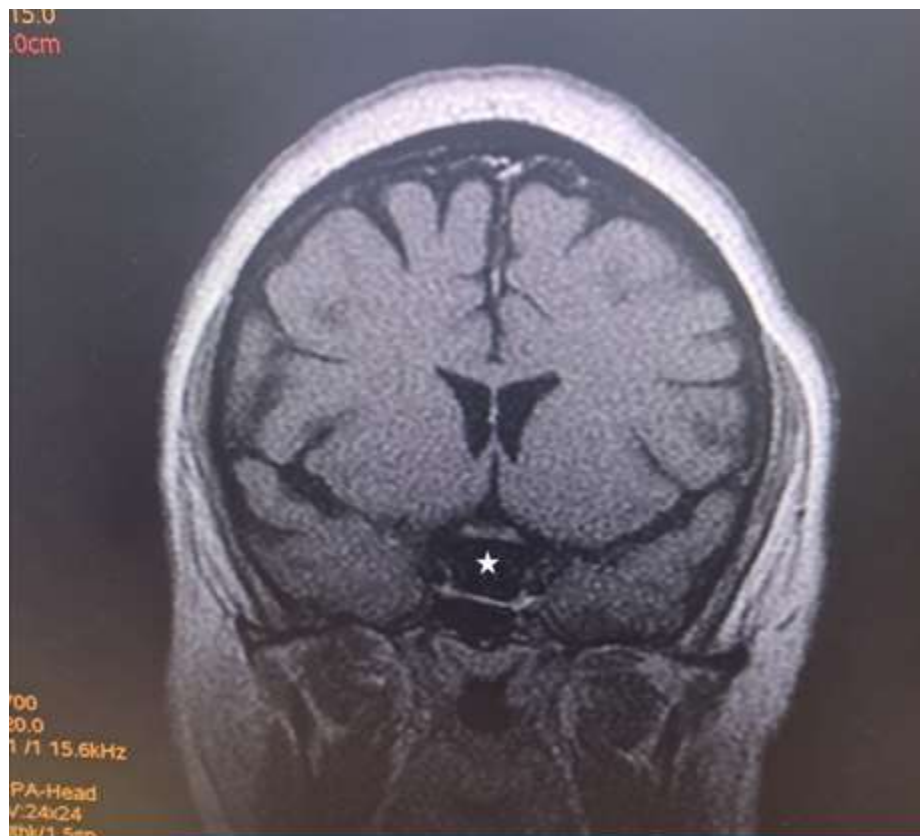

Figure 6: Coronal T1W image of the brain showing a hypointense rounded intrasellar mass lesion (white asterisk)

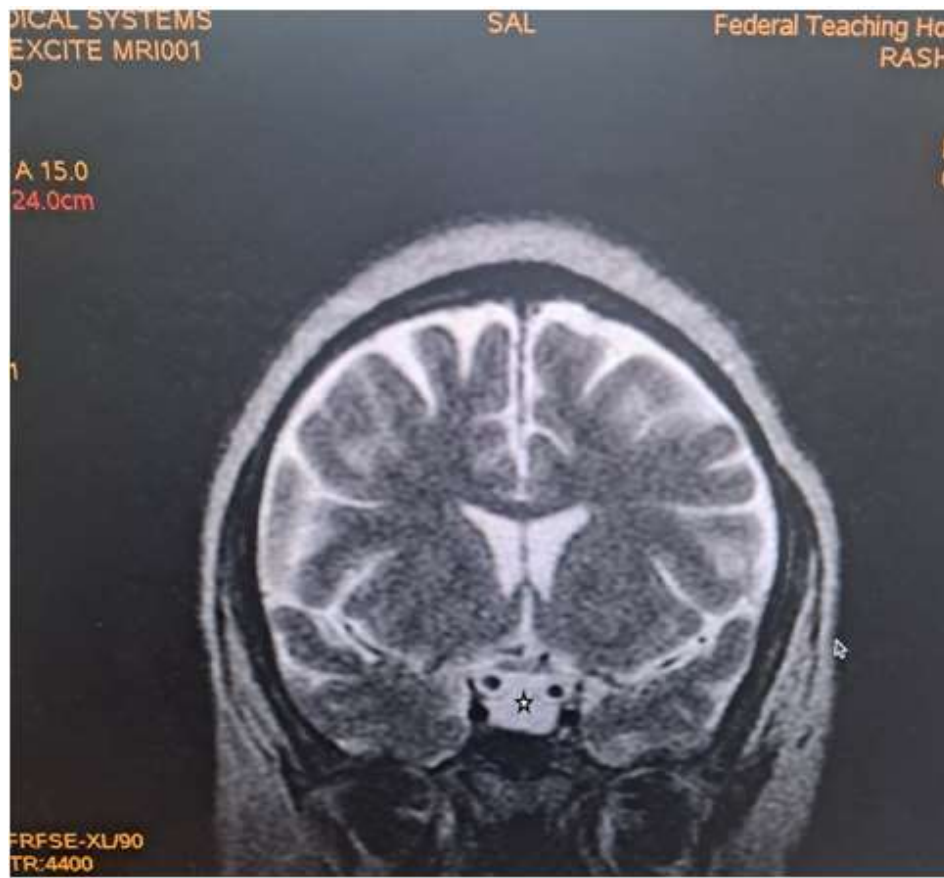


Figure 7: Coronal T1W image of the brain showing a hyperintense rounded intrasellar mass lesion (black asterisk)

Discussion

Rathke cleft cysts (RCC) are non-neoplastic cysts arising from the embryonic remnants of Rathke pouch of the pituitary gland. They occupy the sellar space, but can have suprasellar extension¹.

Their peak incidence falls between the fourth and the sixth decade of life and are three times more frequent among women [5]. It is rarely seen in childhood³. RCC are common incidental findings in 11–22 % of autopsies [2–4]. The case presented was a 35- year old female which falls in the frequent age group of the disease.

Clinically, majority of lesions less than 3mm are asymptomatic⁶. However, when large, the typical symptoms include headache, visual loss and endocrinologic dysfunction^{7,8}. The case presented had recurrent headache, poor vision, amenorrhoea, loss of libido and occasional galactorrhea. No heat or cold intolerance. No convulsion or loss of consciousness. The headache seen is due to raised intracranial pressure from the mass which is non-specific. It may also be due to cyst wall infarction, haemorrhage or leakage of inflammatory contents¹⁴. The poor vision seen is due to compression of the optic chiasma by the cyst, while the amenorrhoea, loss of libido and galactorrhea are the result of the endocrine dysfunction usually seen in the disease [16].

Differential diagnosis of The differential diagnoses of Rathke's cleft cyst includes: Cystic pituitary adenoma, craniopharyngioma, empty sella syndrome and metastasis [17].

Skull radiographs usually show non-specific features of raised intracranial pressure which include widening of the sella tursica, increased convolutional

markings, sutural widening and increased head size due with craniofacial disproportion in favour of the cranium. The skull x-ray of the case presented was however normal.

RCC on Computed Tomography (CT) typically present as a Hypodense sella or suprasellar mass. Cyst wall giving ring enhancement may be present especially with inflammation of the cyst [18]. Wall calcification is seen in 10-15% of cases.

Rathke's cyst is visualised on magnetic resonance imaging as a lesion located in the intermediate lobe of the pituitary. Its largest diameter usually does not exceed 20 mm⁹. The cyst may have varying intensity against the cerebrospinal fluid, although it is more often hypointense in T1-weighted images and hyperintense in T2-weighted images. RCC image captured on MRI is described as "an egg in a shell" [9]. The enhancement of the cyst wall following contrast administration suggests inflammation or metaplasia [11].

Due to its high soft tissue resolution, Magnetic Resonance Imaging (MRI) is the primary diagnostic technique for RCC⁹. It also determines the cystic content and fluidity of the cyst which is useful in planning for subsequent patient's management¹⁰. Fifty percent are hyperintense on T1W (due to high protein content) while 50% are hypointense. On T2W, 70% are hyperintense, 30% iso or hypointense and 20% have hypointense rim. T1W Post contrast images usually show no enhancement. However, a thin enhancing rim may be seen when cyst wall infection is present [19-20]. The case presented revealed expansion of the sella with a well-defined fairly rounded lesion measuring 15 X 14 X 15mm (width X AP X H). It is hypointense on T1W, hyperintense on T2W and suppressed on FLAIR sequence. Rim enhancement is seen post contrast. The mass is inseparable from the optic

chiasma suggestive of compression. The appearance of the cyst confirmed no haemorrhage or debris within the cyst. However, the rim enhancement suggest inflammation of the cyst as explained in the text. The finding of optic chiasma compression may explain the visual impairment and the bitemporal hemianopia seen in the patient.

Definitive treatment modalities for large symptomatic RCC include surgical excision and Radiotherapy¹¹. Hormone replacement therapy is used in patients with endocrine dysfunction. Asymptomatic cases however require observation and serial monitoring [12-13]. The presented patient was placed on Bromocriptin tablets with remarkable improvement of the galactorrhea and normalisation of the prolactin level.

Conclusion:

Rathke cleft cysts (RCC) are non-neoplastic cysts of the sellar which may extend to the suprasellar region presenting with features of raised intracranial pressure, optic pathway compression and endocrine dysfunction. MRI due to its high soft tissue resolution plays an important role in its diagnosis and follow up. Most cases in our environment are under reported or missed due to non-availability of functional MRI or high cost of the study.

References

1. Voelker JL, Campbell RL, Muller J (1991). Clinical, Radiographic, and pathological features of symptomatic Rathke's cleft cysts. *J Neurosurg* 1991; 74(1): 535–544
2. Teramoto A, Hirakawa K, Sanno N, Osamura Y (1994). Incidental pituitary lesions in 1,000 unselected autopsy specimens. *Radiology* 1994; 193(1):161–164
3. Swearingen B, Biller BM (2008). Diagnosis and management of pituitary disorders. *Humana Pr Inc* ISBN: 1588299228. Google Books.
4. Sumida M, Uozumi T, Mukada K et al (1994). Rathke cleft cyst: correlation of enhanced MR imaging and surgical findings. *Am J Neuroradiol.* 15(3):525 – 532.
5. Trifanescu R, Ansorge O, Wass JAH, et al (2012). Rathke's cleft cysts. *Clin Endocrinol*; 76(2): 151–160.
6. Byun WM, Kim OL, Kim D (2000). MR imaging findings of Rathke's cleft cysts: Significance of intracystic nodule. *Am J Neuroradiol* 21(3):485 – 488.
7. Potts MB, Jahangiri A, Lamborn KR, Blevins LS, Kunwar S, et.al (2011). Suprasellar Rathke cleft cysts: clinical presentation and treatment outcomes. *Neurosurgery* ; 69 (1):1058–1068.
8. Kasperbauer JL, Orvidas LJ, Atkinson JL, Abboud CF (2002). Rathke cleft cyst: diagnostic and therapeutic considerations. *Laryngoscope* 2002; 112(91):1836–1839.
9. Han X and Zhao DJ (2010). Imaging diagnosis of Rathke's cleft cyst. *J Med Imag* ; 20: 782–784.
10. Ozoner B, Aydin S, Akgun MY, Durmaz ES, Sahin S, Gazioglu N et al (2019). Predictive factors for Rathke's cleft cyst consistency. *World Neurosurg*; 128:522 – 530.
11. Brassier G, Morandi X, Tayiar E, et al (1999). Rathke's cleft cysts: surgical-MRI correlation in 16 symptomatic cases. *J Neuroradiol.* 1999; 26(3): 162–171,
12. Tate MC, Jahangiri A, Blevins L, et al (2010). Infected Rathke cleft cysts: distinguishing factors and factors predicting recurrence. *Neurosurgery* 67(3): 762–769.
13. Ikeda H, Yoshimoto T (2002). Clinicopathological study of Rathke's cleft cysts. *Clin Neuropathol.* 21(2): 82–91
14. Hama S, Arita K, Nishisaka T, et al (2002). Changes in the epithelium of Rathke cleft cyst associated with inflammation. *J Neurosurg* 96(2): 209–216
15. Komatsu F, Tsugu H, Komatsu M, Sakamoto S, Oshiro S, Fukushima T, Nabeshima K, Inoue T (2010). Clinicopathological characteristics in patients presenting with acute onset of symptoms caused by Rathke's cleft cysts. *Acta Neurochir* ; 152:1673–1678.
16. Trifanescu R, Stavrinides V, Plaha P, et al (2011). Outcome in surgically treated Rathke's cleft cysts: long-term monitoring needed. *Eur J Endocrinol.* 165(1): 33–37.
17. Elżbieta Andrysiak-Mamos, Karol Sagan, Leszek Sagan, Elżbieta Sowińska-Przepiera, Anelli Syrenicz (2018). Cystic lesions of the sellar-suprasellar region-n diagnosis and treatment. *Endokrynologia Polska* ; 69 (2): 212 – 220.
18. Okamoto S, Handa H, Yamashita J et al (1985). Computed Tomography in intra and suprasellar epithelial cysts (symptomatic Rathke cleft cyst). *Am J Neuroradiol.* 6(4):515–519.
19. Pisaneschi M, Kapoor G (2005). Imaging the sella and suprasellar region. *Neuroimaging Clin. N. Am* ; 15(1): 203 – 219.
20. Park M, Lee S, Choi J et al (2015). Differentiation between cystic pituitary Adenomas and Rathke cleft cyst: A diagnostic model using MRI. *Am J Neuroradiol* ; 36(10): 1866- 1873.



This work is licensed under Creative Commons Attribution 4.0 License

To Submit Your Article Click Here:

Submit Manuscript

DOI: [10.31579/2690-8794/252](https://doi.org/10.31579/2690-8794/252)

Ready to submit your research? Choose Auctores and benefit from:

- fast, convenient online submission
- rigorous peer review by experienced research in your field
- rapid publication on acceptance
- authors retain copyrights
- unique DOI for all articles
- immediate, unrestricted online access

At Auctores, research is always in progress.

Learn more <https://auctoresonline.org/journals/clinical-medical-reviews-and-reports>